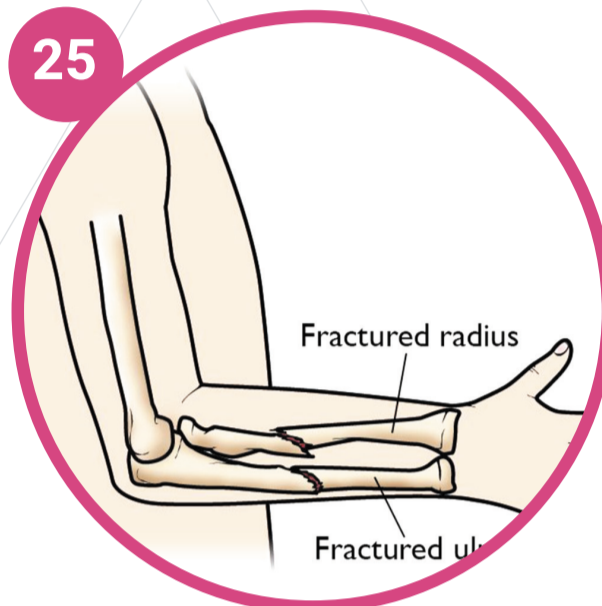


Emergency fractures Quick reference

All open injuries and/or injuries with neurovascular compromise need discussion with appropriate team (orthopaedics or plastics)

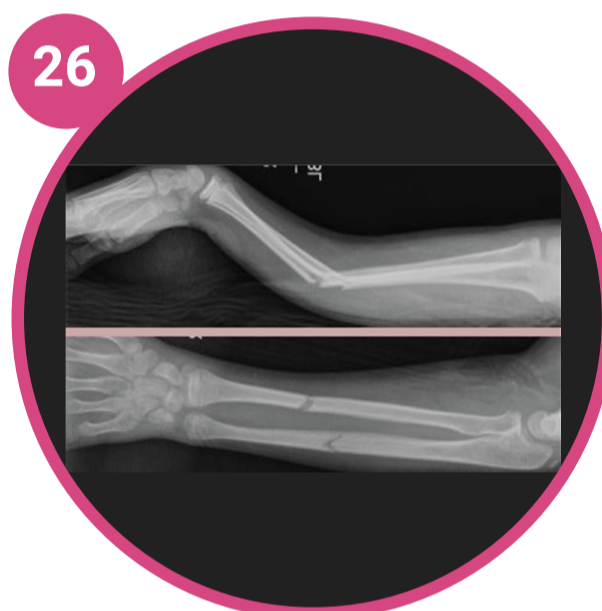
UPPER LIMB | Forearm Upper arm Clavicle



25

Uncomplicated mid-shaft radius & ulnar fractures

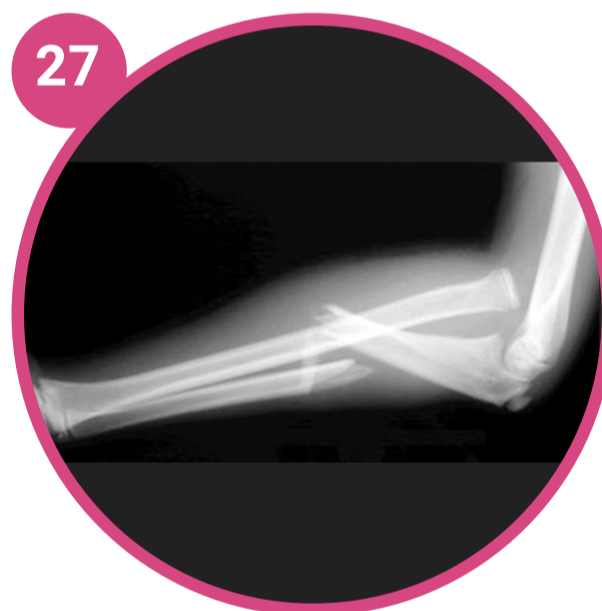
Minimally displaced
Immobilisation: Above elbow backslab
Follow up: Orthopaedics OPD



26

Complicated mid-shaft radius & ulnar fractures

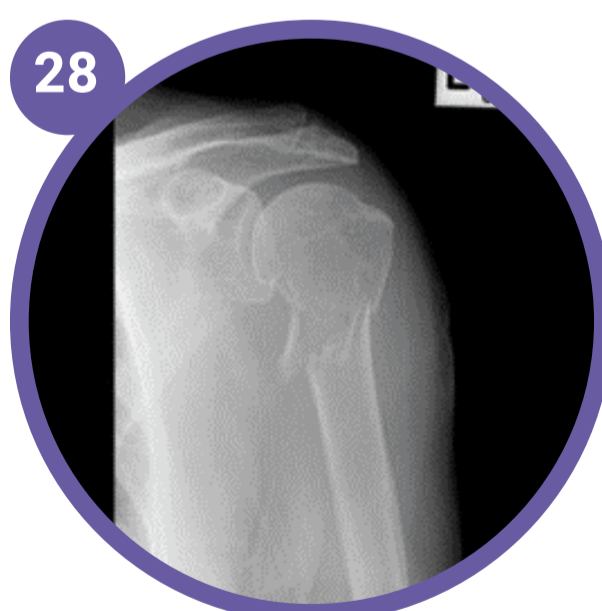
Significantly displaced: $>20^\circ$ dorsal angulation or $>10^\circ$ volar angulation
Discuss with orthos about reduction and ORIF
Immobilisation: Above elbow resting backslab
Follow up: Orthopaedics OPD



27

Monteggia fracture dislocations

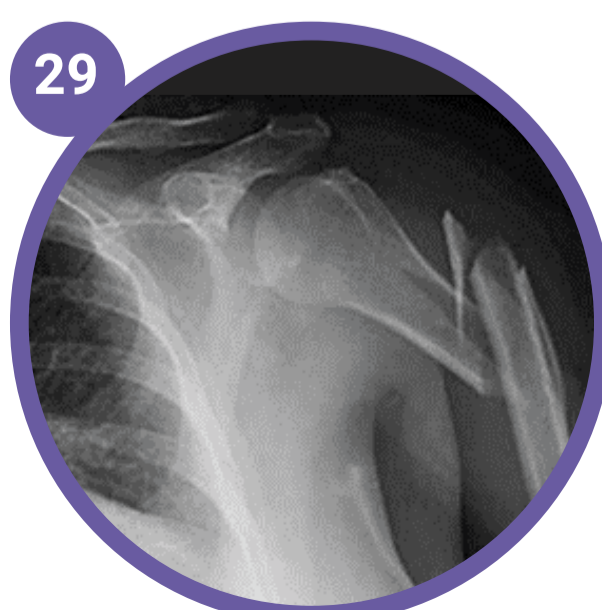
Proximal 1/3 ulnar fracture with associated radial head dislocation
Discuss with orthos about reduction and ORIF
Immobilisation: Above elbow resting backslab
Follow up: Orthopaedics OPD



28

Uncomplicated proximal humerus fractures

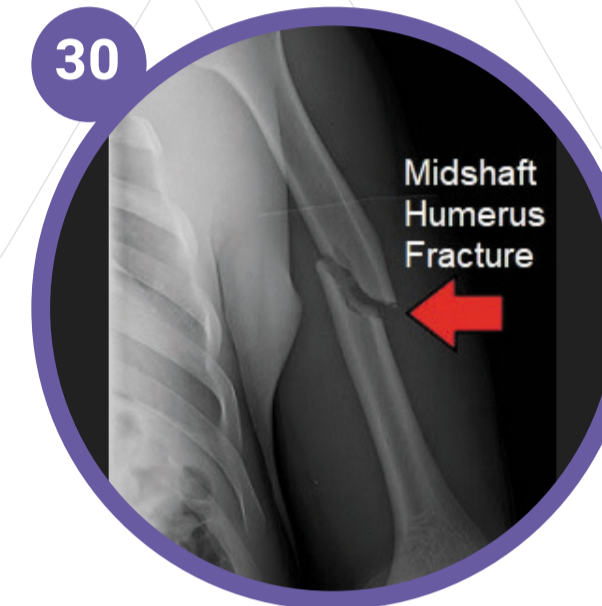
Uncomplicated: $<50\%$ displacement
Immobilisation: High arm collar and cuff
Follow up: Orthopaedics OPD



29

Complicated proximal humerus fractures

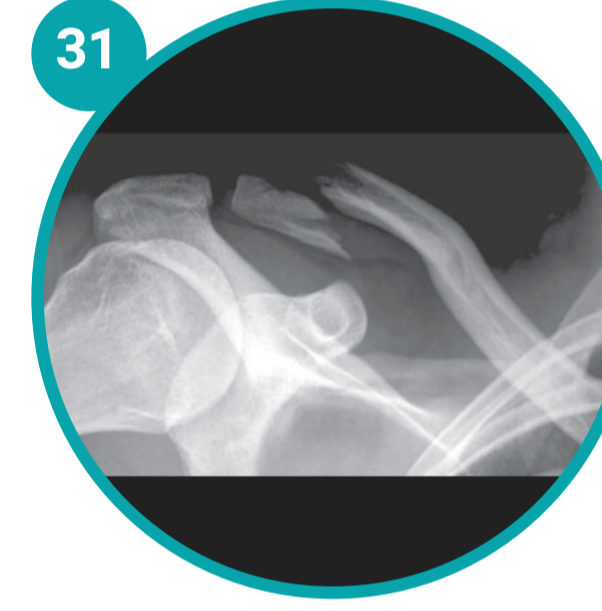Complicated: $>50\%$ displacement
Discuss with orthos about ORIF
Immobilisation: High arm collar and cuff
Follow up: Orthopaedics OPD



30

Uncomplicated humerus shaft fractures

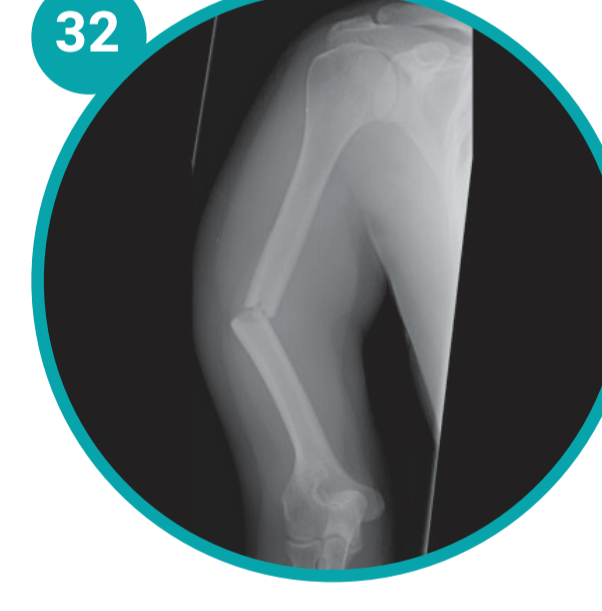
Uncomplicated: $<10^\circ$ angulation
Immobilisation: High arm collar and cuff
Follow up: Orthopaedics OPD



31

Complicated clavicle fractures

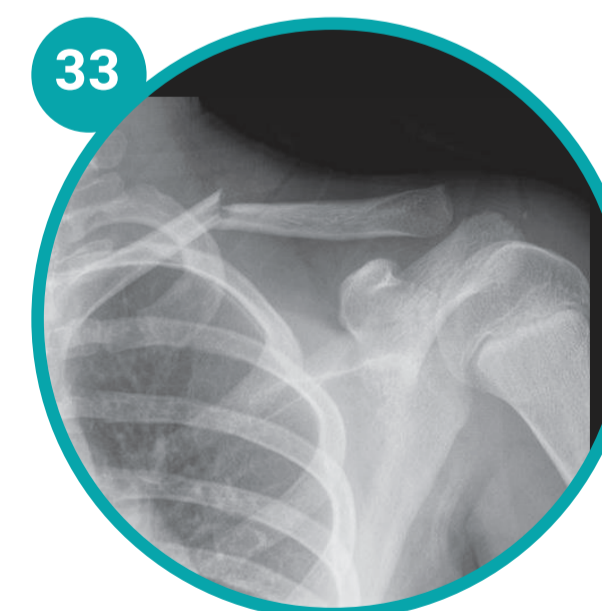
Complicated: Distal & proximal third zone
Discuss with orthos
Immobilisation: Elevated broad arm sling for 3 weeks
Follow up: Orthopaedics OPD
Red Flag: Skin tenting-impending compound, needs discussion with orthos



32

Complicated humerus shaft fracture

Complicated: $>10^\circ$ angulation
Discuss with orthos about ORIF
Immobilisation: U-slab
Follow up: Orthopaedics OPD

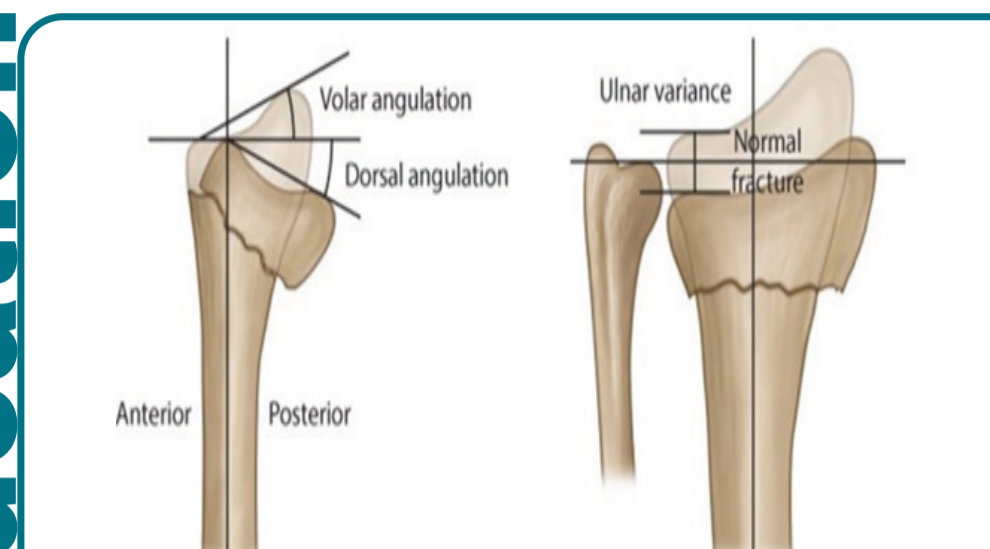


33

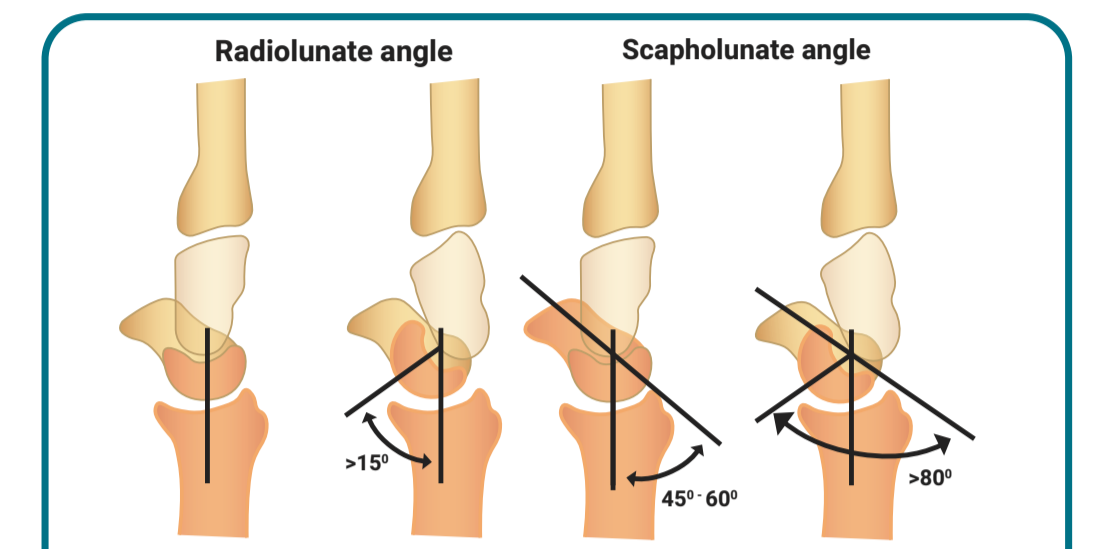
Uncomplicated clavicle fractures

Uncomplicated: Mid-third zone
Immobilisation: Elevated broad arm sling for 3 weeks
Follow up: Orthopaedics OPD
Red Flag: Skin tenting-impending compound, needs discussion with orthos

Education

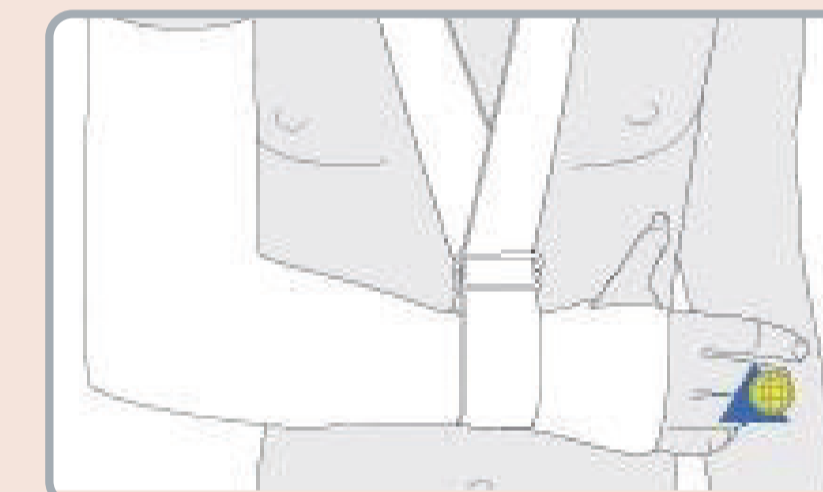


Measuring distal radius fractures displacements



Radiolunate angle & scapholunate angle measurements

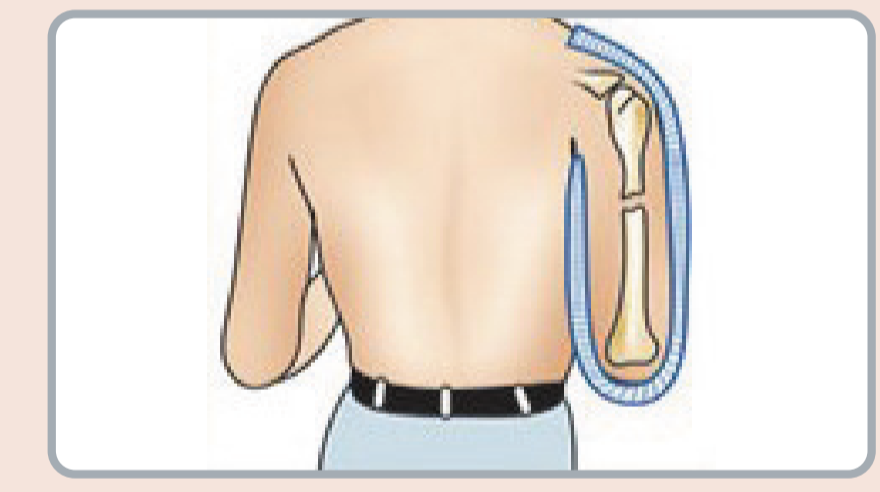
Treatment and intervention



Above elbow backslab

· 90° elbow flexion

25 26 27



U-Slab

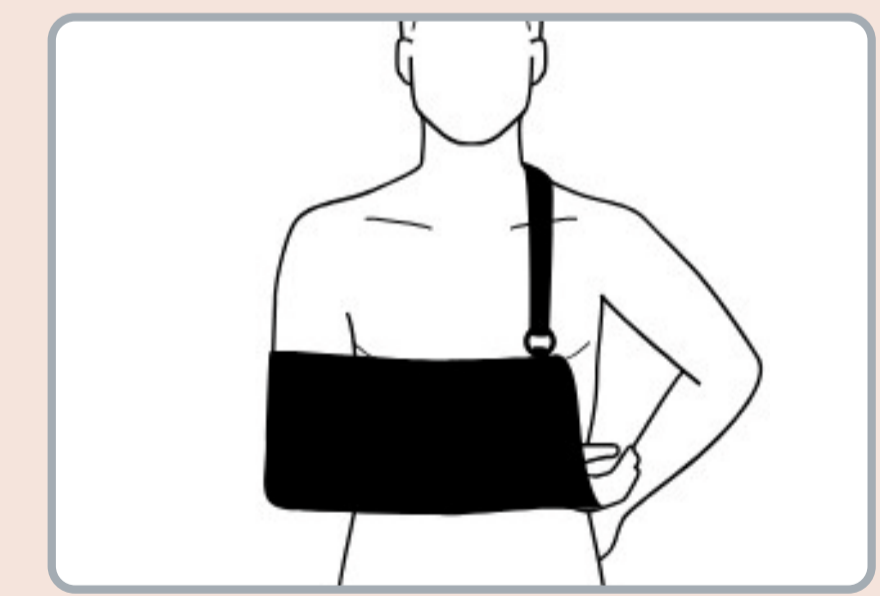
· the plaster must extend passed the fracture site

32



High arm collar & cuff

28 29 30



Broad arm sling no backstrap

31 33