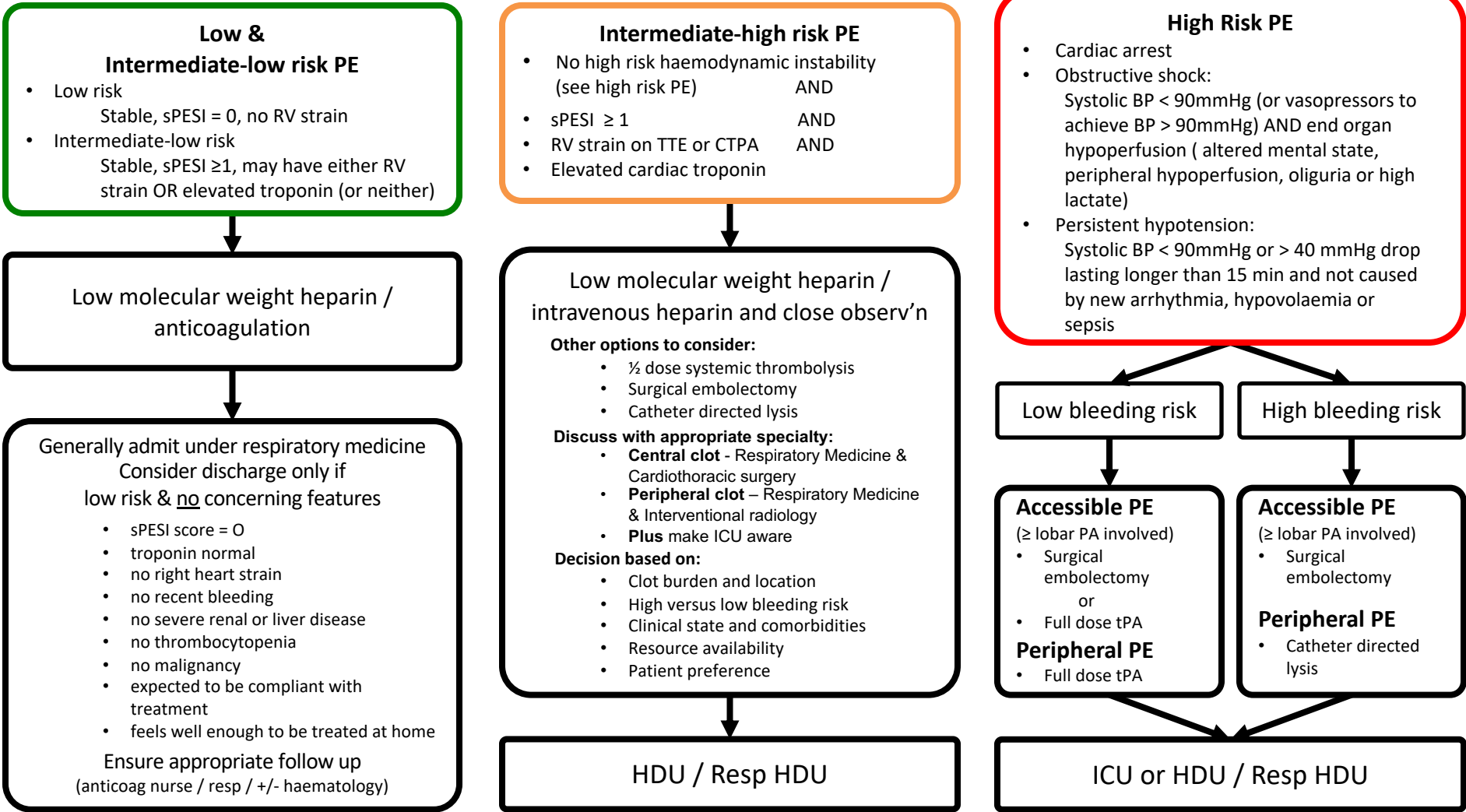




# Sir Charles Gairdner Hospital

## Pulmonary Embolism Advanced Care Pathway

A senior clinician should be involved in the assessment of patients with pulmonary embolism, and discussion between emergency medicine, respiratory medicine, cardiothoracic surgery and interventional radiology is encouraged. These are only guidelines, patients are unique, there is a broad and complex spectrum of presentation, and definitive evidence is limited.





### High bleeding risk and contraindications to thrombolysis

#### Absolute

- Known allergy / hypersensitivity / adverse reaction to thrombolytics or allergy to Gentamicin ( a trace residue from the manufacturing process)
- Active or recent internal bleeding within 14 days (excludes menstruation)
- Significant closed head, facial or other severe trauma within past 3 months
- Suspected aortic dissection or pericarditis
- Prior intracranial haemorrhage within past 6 months
- Ischaemic stroke within 3 months or previous haemorrhagic stroke
- Known structural cerebral vascular lesion (AVM or aneurysm)
- Known malignant intracranial or intraspinal neoplasm
- Known severe bleeding disorder
- Recent (within past 2 months) intracranial or intraspinal surgery)

#### Relative

- Age more than 75 years
- Current anticoagulant use (if on warfarin only thrombolysate if INR <2.0)
- Non compressible vascular puncture within past 10 days
- Recent major surgery (within 3 weeks)
- Traumatic or prolonged CPR (for more than 10 minutes)
- Recent internal bleeding (within 2-4 weeks)
- History severe chronic poorly controlled
- Hypertension
- Uncontrolled hypertension on presentation (Systolic >180 or diastolic >110mmHg)
- Ischaemic stroke over 3 months ago
- Dementia or known intracranial pathology
- Pregnancy or recent delivery
- Reduced GCS
- Haemorrhagic ophthalmic conditions
- Active peptic ulcer or other ulcerative conditions (i.e. Crohn's disease)
- Advanced kidney or liver disease
- Prior Streptokinase / Alteplase / Reteplase

### Consideration of imaging for source of PE and need for IVC filter

- In patients with suspected high risk or intermediate-high risk PE, CTPA with concurrent CTV down to popliteal veins is recommended.
- Where CTV is not prospectively performed ultrasound of the lower limbs is an alternative and strongly recommended if considering major Rx (lysis, cath, embolectomy).
- IVC filter is placed in patients who have undergone surgical pulmonary embolectomy and in whom there remains significant lower limb thrombus.
- IVC filter is considered in patients with intermediate-high risk PE, in whom there remains significant lower limb thrombus, particularly if it appears unstable.
- Advice on the use of TED stockings is available on the SCGH ED DVT pathway

### Administration of thrombolysis for pulmonary embolism

#### Full dose thrombolysis

Alteplase (tPA)

> 65kg 10mg IV bolus, followed by 90mg IV infusion over 2 hours

< 65kg adjust dose so it does not exceed 1.5mg/kg; give 10mg IV bolus then the remainder of the dose over 2 hours

(or Tenecteplase weight adjusted bolus over 5 to 10 seconds; range 30-50mg; step up 5mg / 10kg from 60kg to 90kg)

#### Half dose thrombolysis

Alteplase (tPA) (there is no evidence for Tenecteplase at half-dose – use Alteplase)

> 65kg 10mg IV bolus, followed by 40mg IV infusion over 2 hours

< 65kg adjust dose so it does not exceed 0.75mg/kg; give 10mg IV bolus then the remainder of the dose over 2 hours

Follow the Alteplase 2 hour infusion with anticoagulation with unfractionated heparin via IV infusion as per anticoagulation chart protocol.

#### Catheter directed thrombolysis

Alteplase (tPA) as directed by interventional radiology

### sPESI Score

Age in years	≤80	0	>80	+1
Hx of cancer	No	0	Yes	+1
Hx chronic cardiopulmonary disease	No	0	Yes	+1
Heart rate, bpm	<110	0	≥110	+1
Systolic BP, mmHg	≥100	0	<100	+1
O2 Sats	≥ 90	0	< 90	+1