

VOLAR SLAB

carpal, metacarpal, finger injuries

HAND POSITION

- hand in supination
- MCP 70° flexed
- wrist 30° dorsiflexed

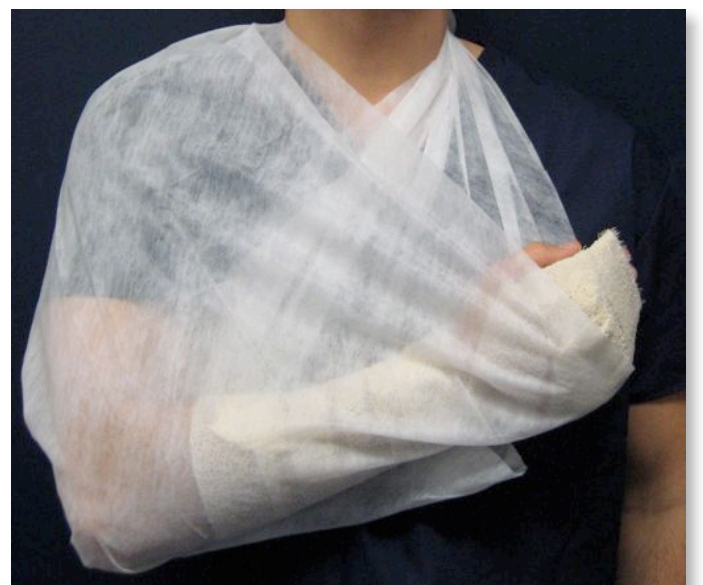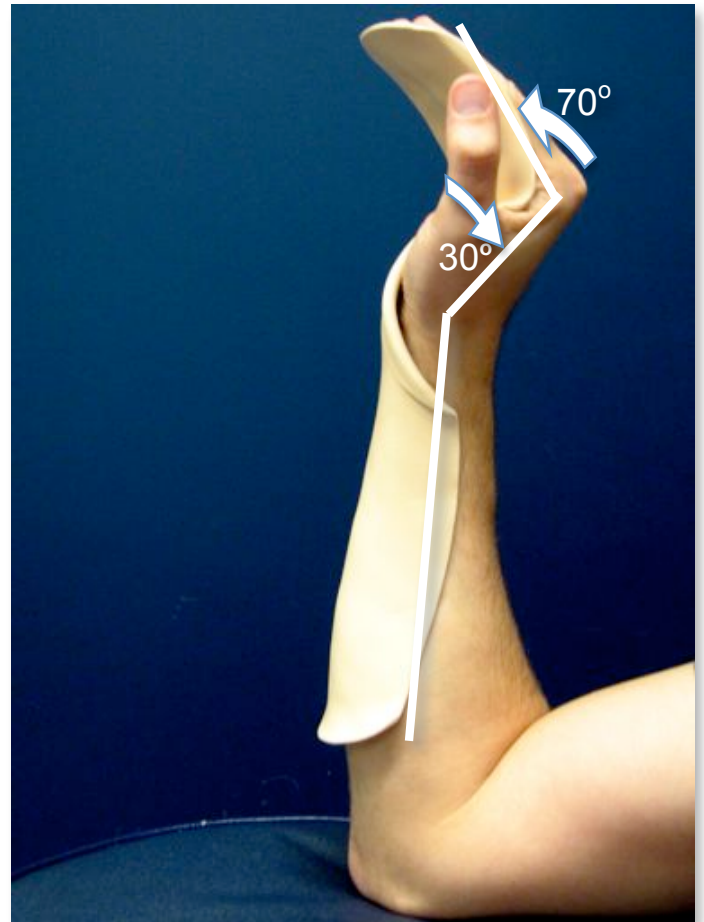
PLASTER POSITION

- 6-8 layers of 12cm plaster cut to template, covered in padding (plastic model shown here)
- extend distally past the fingertips
- extend proximally as far as possible without it impinging elbow flexion
- encircle with crepe

SLING POSITION

- keep # above level of heart
- keep sling on until swelling has gone down
- refer to plastics outpatients (fractures distal to carpal bones is plastics OPD not # clinic)

further information: McCrae's 'Practical management of fracture management'



please have your plaster reviewed by the consultant (or senior night registrar)